

Mark Deuss
 Veterinary Surgeon

Steyvershofstraat 37
 3640 Kinrooi (B)
 Tel. 0(031)6 537 537 01
 mark.deuss@hotmail.com

Examination Report

"HOT DREAM SEMILLY"
 (DIAMANT DE SEMILLY)

Examination for the purpose of purchase, sale insurance

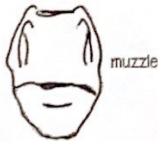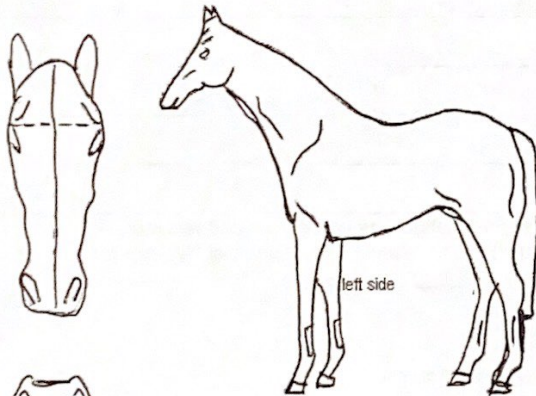
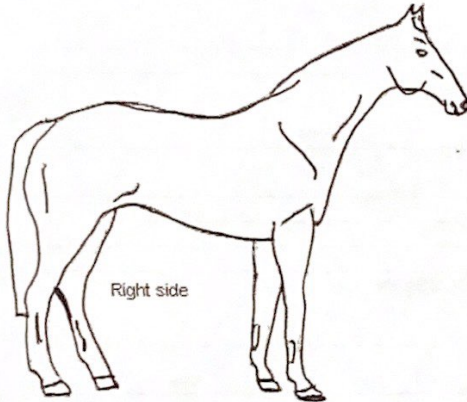
Company: _____
 Horse/Pony is used for: SPORTS
 Client: _____
 Address: _____
 Postal code and town: _____
 Buyer Seller Owner: _____
 Present Yes/No _____

Description

Race or Type: _____
 Pedigree no.: 25000117545
 Age: 2017
 Sex: GELDING
 Shoulder height: _____
 Level of training: SPORTS
 Colour: BAY
 Outline: _____

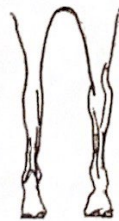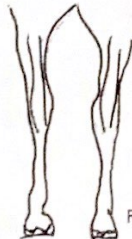de STUDBOOKPAPERS

microchipnr.: 250258500185169



Hind rear view

fore rear view



Left

Right

Left

Right

General Examination

Build and posture good/deviant: _____
 Feeding condition good/deviant: _____
 Skin and hair good/deviant: _____
 Pulse in condition of rest/possibly after labour: NO
 Respiration in condition of rest/possibly after labour: NO
 Type of respiration normal/deviant: _____
 Mucous membranes normal/deviant: _____
 Lymph glands normal/deviant: _____
 Eyes normal/deviant: _____
 Mouth normal/deviant: _____
 Spontaneous cough present/not present: _____
 Larynx normal/sensitive: _____
 Cicatrice corne operation: present/not present: _____

Further clinical examination

	not deviant	deviant
Respiratory system	<input checked="" type="checkbox"/>	<input type="checkbox"/>
Laryngoscopy if necessary	<input type="checkbox"/>	<input type="checkbox"/>
Circulation system	<input checked="" type="checkbox"/>	<input type="checkbox"/>
Digestion system	<input checked="" type="checkbox"/>	<input type="checkbox"/>
Urogenital system	<input checked="" type="checkbox"/>	<input type="checkbox"/>
Nervous system	<input checked="" type="checkbox"/>	<input type="checkbox"/>

Motion system:

Inspection	<input checked="" type="checkbox"/>	<input type="checkbox"/>
Palpation	<input checked="" type="checkbox"/>	<input type="checkbox"/>
Percussion	<input checked="" type="checkbox"/>	<input type="checkbox"/>

Neck	<input checked="" type="checkbox"/>	<input type="checkbox"/>
Withers	<input checked="" type="checkbox"/>	<input type="checkbox"/>
Back	<input checked="" type="checkbox"/>	<input type="checkbox"/>
Groin	<input checked="" type="checkbox"/>	<input type="checkbox"/>
Left forefoot	<input checked="" type="checkbox"/>	<input type="checkbox"/>
Right forefoot	<input checked="" type="checkbox"/>	<input type="checkbox"/>
Left hind leg	<input checked="" type="checkbox"/>	<input type="checkbox"/>
Right hind leg	<input checked="" type="checkbox"/>	<input type="checkbox"/>

Fronts hoofs

	equal	not equal
Horn quality	<input checked="" type="checkbox"/>	<input type="checkbox"/>
Hoof percussion	<input checked="" type="checkbox"/>	<input type="checkbox"/>
Hoof visitation	<input checked="" type="checkbox"/>	<input type="checkbox"/>

not deviant deviant

Walking on hard ground

straight line

Left small volt

Right small volt

Trotting on hard ground

straight line

left small volt

right small volt

Trotting on soft ground

left volt

right volt

Cantering/Galloping on soft ground

left volt

right volt

Bending tests

Tightening of lower foot or leg

Left forefoot ~~not sensitive~~/sensitive

Right forefoot ~~not sensitive~~/sensitive

Left hind leg ~~not sensitive~~/sensitive

Right hind leg ~~not sensitive~~/sensitive

Trotting off after two minutes bending

LF -1 +/- +/- ++

RF -1 +/- +/- ++

LH -1 +/- +/- ++

RH -1 +/- +/- ++

L -1 +/- +/- ++

R -1 +/- +/- ++

Hock:

Fixing the kneecap

L not possible / possible

R not possible / possible

Number: "HOT DREAM Semilly"

After the examination blood/no blood was taken to search for illegal practices.

If necessary laboratory results:

JN CONSIGNATION

FINAL CONCLUSION

AFTER my CLINICAL & RADIOLOGICAL EXAMINATION: THIS HORSE IS USEFUL FOR SPORTS ON THE DAY OF THE EXAMINATION IE 22/2/2022

if necessary conductivity anaesthesia in consultation with the owner:

The examination was carried out and reported by Mark Deuss, Veterinary surgeon at Kinrooi on: (date) 01/MARCH/2022

Results of the X-ray examination

	good	fair	bad
Navicular LF	<input checked="" type="checkbox"/>	<input checked="" type="checkbox"/>	<input type="checkbox"/> 2
Navicular RF	<input checked="" type="checkbox"/>	<input type="checkbox"/>	<input type="checkbox"/> 2
Fetlock LF	<input checked="" type="checkbox"/>	<input type="checkbox"/>	<input type="checkbox"/> 1-2
Fetlock RF	<input checked="" type="checkbox"/>	<input type="checkbox"/>	<input type="checkbox"/> 2
Fetlock LH	<input checked="" type="checkbox"/>	<input type="checkbox"/>	<input type="checkbox"/> 1-2
Fetlock RH	<input checked="" type="checkbox"/>	<input type="checkbox"/>	<input type="checkbox"/> 2
Hock L	<input checked="" type="checkbox"/>	<input type="checkbox"/>	<input type="checkbox"/> 1-2
Hock R	<input checked="" type="checkbox"/>	<input type="checkbox"/>	<input type="checkbox"/> 1-2
Stifle L	<input checked="" type="checkbox"/>	<input type="checkbox"/>	<input type="checkbox"/> 1-2
Stifle R	<input checked="" type="checkbox"/>	<input type="checkbox"/>	<input type="checkbox"/> 1-2

(Signature and stamp)

Mark Deuss
 Veterinary Surgeon
 Sleyvershofstraat 37
 3640 Kinrooi (B)
 Tel. 0031 6 537 587 01

Necessary results of any other x-ray examinations

PASTERN JOINT RF: VERY SMALL IRREGULARITY

FETLOCK RF: SMALL FRAGMENT DORSAL

X-RAYS BACK: NO SIGNIFICANT ABNORMALITIES (PROX. 2 PROCESSI SMALL IRREGULARITY = NO PROBLEM)