

Mark Deuss
 Veterinary Surgeon

Steyvershofstraat 37
 3640 Kinrooi (B)
 Tel. 0(031)6 537 537 01
 mark.deuss@hotmail.com

Examination Report

"IN THE MOOD 2"
 (JDEAL DE LA LOGE)

Examination for the purpose of purchase, sale insurance

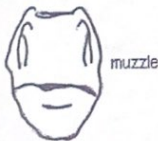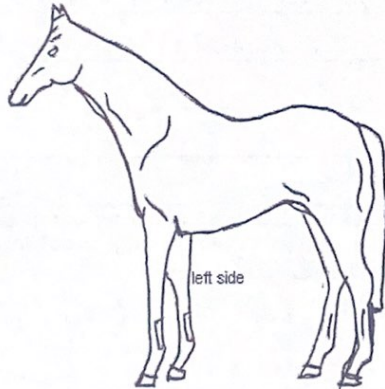
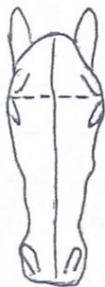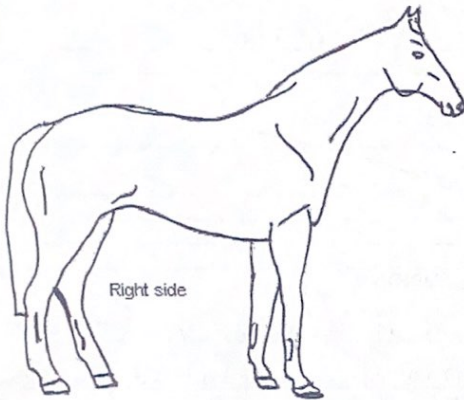
Company: _____
 Horse/Pony is used for: Sports
 Client: _____
 Address: _____
 Postal code and town: _____
 Buyer Seller Owner: _____
 Present Yes/No _____

Description

Race or Type: Z
 Pedigree no.: 056015 Z 55157419
 Age: 18/04/2019
 Sex: FEMALE
 Shoulder height: _____
 Level of training: Sports
 Colour: Chestnut
 Outline: _____

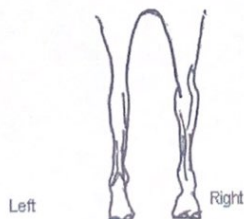
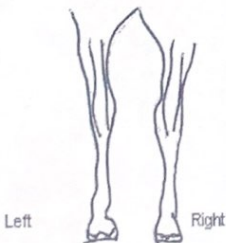
cf. STUDBOOKPAPER!

Microchip no.: 981100004475732



Hind rear view

fore rear view



General Examination

Build and posture good/deviant: _____
 Feeding condition good/deviant: _____
 Skin and hair good/deviant: _____
 Pulse in condition of rest/possibly after labour: no
 Respiration in condition of rest/possibly after labour: no
 Type of respiration normal/deviant: _____
 Mucous membranes normal/deviant: _____
 Lymph glands normal/deviant: _____
 Eyes normal/deviant: _____
 Mouth normal/deviant: _____
 Spontaneous cough present/not present: _____
 Larynx normal/sensitive: _____
 Cicatrice corne operation: present/not present: _____

Further clinical examination

	not deviant	deviant
Respiratory system	<input checked="" type="checkbox"/>	<input type="checkbox"/>
Laryngoscopy if necessary	<input checked="" type="checkbox"/>	<input type="checkbox"/>
Circulation system	<input checked="" type="checkbox"/>	<input type="checkbox"/>
Digestion system	<input checked="" type="checkbox"/>	<input type="checkbox"/>
Urogenital system	<input checked="" type="checkbox"/>	<input type="checkbox"/>
Nervous system	<input checked="" type="checkbox"/>	<input type="checkbox"/>

Motion system:

Inspection	<input checked="" type="checkbox"/>	<input type="checkbox"/>
Palpation	<input checked="" type="checkbox"/>	<input type="checkbox"/>
Percussion	<input checked="" type="checkbox"/>	<input type="checkbox"/>

Neck	<input checked="" type="checkbox"/>	<input type="checkbox"/>
Withers	<input checked="" type="checkbox"/>	<input type="checkbox"/>
Back	<input checked="" type="checkbox"/>	<input type="checkbox"/>
Groin	<input checked="" type="checkbox"/>	<input type="checkbox"/>
Left forefoot	<input checked="" type="checkbox"/>	<input type="checkbox"/>
Right forefoot	<input checked="" type="checkbox"/>	<input type="checkbox"/>
Left hind leg	<input checked="" type="checkbox"/>	<input type="checkbox"/>
Right hind leg	<input checked="" type="checkbox"/>	<input type="checkbox"/>

	equal	not equal
Fronts hoofs	<input checked="" type="checkbox"/>	<input type="checkbox"/>
Horn quality	<input checked="" type="checkbox"/>	<input type="checkbox"/>
Hoof percussion	<input checked="" type="checkbox"/>	<input type="checkbox"/>
Hoof visitation	<input checked="" type="checkbox"/>	<input type="checkbox"/>

not deviant deviant

Walking on hard ground

straight line
 Left small volt
 Right small volt

Trotting on hard ground

straight line
 left small volt
 right small volt

Trotting on soft ground

left volt
 right volt

Cantering/Galloping on soft ground

left volt
 right volt

Bending tests

Tightening of lower foot or leg

Left forefoot not sensitive/sensitive
 Right forefoot not sensitive/sensitive
 Left hind leg not sensitive/sensitive
 Right hind leg not sensitive/sensitive
 Trotting off after two minutes bending

LE (-) +/- ++
 RF (-) +/- ++
 LH (-) +/- ++
 RH (-) +/- ++
 L (-) +/- ++
 R (-) +/- ++

Hock:

Fixing the kneecap

L not possible / possible
 R not possible / possible

Number: JW THE MOOD 2

After the examination blood was taken to search for illegal practices.
 If necessary laboratory results:

JW CONSIGNATION

FINAL CONCLUSION

CLINICAL IN GENERAL A

POSITIVE ADVICE D.D. 23/APRIL/2022

RADIOLOGICAL (D.D. 18/03/2022)

SEE REMARKS

if necessary conductivity anaesthesia in consultation with the owner:

The examination was carried out and reported by
 Mark Deuss, Veterinary surgeon at Kinrooi on:
 (date) 23/APRIL/2022

Results of the X-ray examination

D.D. 18/03/2022 (TAKEN BY VET WIM HANSEN)

	good	fair	bad
Navicular	LF <input checked="" type="checkbox"/>	<u>till</u> <input checked="" type="checkbox"/>	<input type="checkbox"/> 2
Navicular	RF <input type="checkbox"/>	<input type="checkbox"/>	<input type="checkbox"/> 1-2
Fetlock	LF <input checked="" type="checkbox"/>	<input type="checkbox"/>	<input type="checkbox"/> 1-2
Fetlock	RF <input checked="" type="checkbox"/>	<input type="checkbox"/>	<input type="checkbox"/> 1-2
Fetlock	LH <input type="checkbox"/>	<input checked="" type="checkbox"/>	<input type="checkbox"/> 2+
Fetlock	RH <input checked="" type="checkbox"/>	<input type="checkbox"/>	<input type="checkbox"/> 1-2
Hock	L <input checked="" type="checkbox"/>	<input type="checkbox"/>	<input type="checkbox"/> 1-2
Hock	R <input checked="" type="checkbox"/>	<input type="checkbox"/>	<input type="checkbox"/> 1-2
Stifle	L <input checked="" type="checkbox"/>	<input type="checkbox"/>	<input type="checkbox"/> 1-2
Stifle	R <input checked="" type="checkbox"/>	<input type="checkbox"/>	<input type="checkbox"/> 1-2

(Signature and stamp)

Mark Deuss
 Veterinary Surgeon
 Steyvershofstraat 87
 8840 Kinrooi (B)
 Tel. 0031 6 537 537 01

Necessary results of any other x-ray examinations

NAVICULAR LF: FRAGMENT DISTAL BORDER NAVICULAR T SOME
FETLOCK LH: FRAGMENTS PLANTAIR CANICULI