

Examination report

(Formulated by the Netherlands Equine Veterinary Association of the Royal Netherlands Veterinary Association. The pre-purchase examination was performed using the handbook "De veterinaire keuring van het paard" issue 2007 as a guidance.)

Number: E 105567

Examination report

Number: E 105567

Signalment

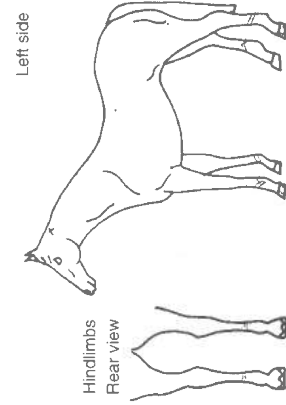
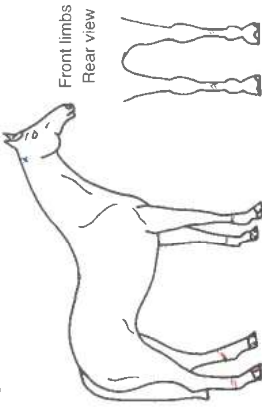
Name: Nybakon
 Breed or type: WUPN
 Studbook no: 18 06162
 Microchip number: 528210004865931
 Pedigree: Sabouche Rouet x Cantos
 Age: 22.05.2018 Sex: gelding
 Coat colour: bay Height at withers ±:

Markings

Location where the exam takes place: Stuifjarm

Head: _____
 LF: _____
 RF: _____
 Other: _____

Right side



Evidence seen of possible behavioural vices? yes / no (if yes: detail: _____)
 Blood collected and put into custody by the examining veterinary surgeon? yes / no
 Blood sample tested for prohibited substances at client's request? yes / no

Veterinary practice (stamp) **ZEDDAM EQUINE CLINIC**
 Hank van Campen DVM
 Tel: +31(0)314 - 663000
 info@zdp.dz.nl

- The examining veterinary surgeon and/or veterinary practice shall not be held liable for loss or damage caused as a result of the performance of the examination or as a result of inaccuracies or omissions in their presentation of this report.
- The client shall be held responsible for the loss or damage of the horse or the horse's property during the veterinary examination.
- The veterinary practice shall not be held liable for the loss or damage of the horse or the horse's property during the veterinary examination.
- The veterinary practice shall not be held liable for the loss or damage of the horse or the horse's property during the veterinary examination.
- The veterinary practice shall not be held liable for the loss or damage of the horse or the horse's property during the veterinary examination.
- The veterinary practice shall not be held liable for the loss or damage of the horse or the horse's property during the veterinary examination.
- The veterinary practice shall not be held liable for the loss or damage of the horse or the horse's property during the veterinary examination.

CONCLUSION:

Positive advice based on clinical examination

Thus examined and reported by me:

JJ van Campen
 veterinary surgeon in:
Zeddam, NL

This report can relate only to the appearance on the date of examination:

17.03.2018

Signature of examining veterinary surgeon:

[Handwritten signature]

Signature of Client:

General and clinical examination

conformation and stance normal abnormal
 condition normal abnormal
 skin and coat normal abnormal
 mucous membranes normal abnormal
 lymph nodes normal abnormal
 eyes and eyelids normal abnormal
Respiratory system
 respiration at rest normal abnormal
 type of respiration normal abnormal
 spontaneous coughing normal abnormal
 respiration after exercise normal abnormal
 abnormal sounds normal abnormal
 laryngoscopy performed normal abnormal
 laryngoscopy findings normal abnormal
Circulatory system
 peripheral circulation normal abnormal
 heart at rest normal abnormal
 heart after exercise normal abnormal
Digest. system (ext. insp.) normal abnormal
 mouth, teeth, tongue normal abnormal
Urogen. system (ext. insp.) normal abnormal
Nervous system
 tail tone normal abnormal
 correction reflexes normal abnormal
 coordination normal abnormal

Inspection, palpation and eventual percussion

head normal abnormal
 neck normal abnormal
 withers normal abnormal
 back normal abnormal
 croup normal abnormal
 left frontlimb normal abnormal
 right frontlimb normal abnormal
 left hindlimb normal abnormal
 right hindlimb normal abnormal
Hooves
 horn quality normal abnormal
 hoof percussion normal abnormal
 hoof shape even/uneven higher than
 shoeing no / front / back and hind

Walk, trot and canter

Walking on hard surface
 straight line normal abnormal
 small circle on the left normal abnormal
 small circle on the right normal abnormal
Trotting on hard surface
 straight line normal abnormal
 small circle on the left normal abnormal
 small circle on the right normal abnormal
Trotting on soft surface
 small circle on the left normal abnormal
 small circle on the right normal abnormal
Cantering on soft surface
 small circle on the left normal abnormal
 small circle on the right normal abnormal

Flexion tests:

Forced flexion:
 LF not sensitive / sensitive LF ± ++
 RF not sensitive / sensitive RF ± ++
 LH not sensitive / sensitive LH ± ++
 RH not sensitive / sensitive RH ± ++

Radiological examination performed: yes no
 Number of X rays: _____

Assessment of radiographs:

Grading
 Navicular bone LF RF
 Fetlock joint LF RF
 Sesamoid bones LF RF
 Tarsal joint LH RH

Fragments

Fetlock joint LF RF
 Fetlock joint LF RF
 Stifle joint LH RH
 Stifle joint LH RH
 Tarsal joint LH RH
 Tarsal joint LH RH
 Fetlock joint LF RF
 Fetlock joint LF RF
 Stifle joint LH RH
 Tarsal joint LH RH
 Fetlock joint LF RF
 Fetlock joint LF RF

Radiological exam of other parts / extra findings:

Other remarks:

#1 weight loss upper jaw