

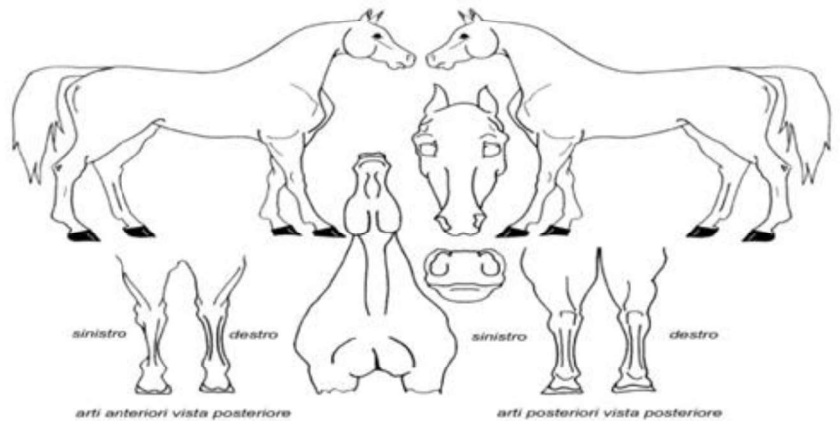
**DOTT. ANDREA TOTO**  
**MEDICO VETERINARIO**  
TEL. 349 3681259  
N° ISCRIZIONE 919 FIRENZE  
VIA GUARDUCCI 18, 59100 PRATO (PO)  
P IVA 02449920970 C.F.TTONDR87E13D612S

### PREPURCHASE VISIT

Date: 06/09/2022

#### IDENTIFICATION

Name: GIRLY DIMAVI  
Breed: Selle Francais  
Sex: Female  
Colour: grey  
Date of birth: 01/08/2016  
Microchip: 250259600559940



#### CLINICAL EXAMINATION

##### General:

Skeletal development and constitution: Normal  
Nutrition and muscle tone: Normal  
Sensory: Normal  
Attitudes and particular signs:  
Vices: Normal  
Skin and subcutaneous connective tissue: small wound, medial, third metatarsal bone right hind limb  
Neurectomy scars: No      Laparotomy: No  
Mucous: Normal      TRC: <2 sec.  
Explorable lymph nodes: Normal  
GFO: Normal

##### Sensory organs:

Eyes: Normal  
Pupillary reflex: Normal  
Ears: Normal      Hearing: Normal

##### Nervous system:

Motor coordination: Normal  
Cranial nerve and skin sensitivity examinations: Normal  
Tail tension: Normal

##### Cardiovascular system:

Heart auscultation: Normal  
Heart Rate at rest: 32 bpm

##### Respiratory system:

Lungs auscultation: Normal  
15 apm  
Breath rate at rest:  
Lungs limits: Normal  
Spontaneous cough: No      After manual stimulation: no  
Breathing noises during work: No

##### Gastrointestinal system:

Mouth: Normal      Teeth: very slight maxillary prognathism  
Abdominal sounds: Normal

**DOTT. ANDREA TOTO**  
**MEDICO VETERINARIO**  
TEL. 349 3681259  
N° ISCRIZIONE 919 FIRENZE  
VIA GUARDUCCI 18, 59100 PRATO (PO)  
P IVA 02449920970 C.F.TTOND87E13D612S

**Inspection and palpation:**

Head:	Normal
Neck:	Normal
Back lumbar region:	Normal
Sacroiliac region:	Normal
Inguinal region:	Normal
Genital organs:	Normal
Right front limb:	Normal
Left front limb:	Normal
Right hind limb:	Small wound, medial face, third metatarsal bone
Left hind limb:	Scar, dorso-lateral face third metatarsal bone, on splint bone
Hoof:	Normal
Frog:	Normal
Note:	

**Dynamic examination**

Step on hard ground	
Straight line:	Normal
right hand circle:	Normal
left hand circle:	Normal
Back:	Normal
Trot on hard ground:	
Straight line:	Normal
right hand circle:	Normal
left hand circle:	Normal
Trot on soft ground	
Straight line:	Normal
right hand circle:	Normal
left hand circle:	Normal
Gallop on soft ground	
right hand circle:	Normal
left hand circle:	Normal

**Flexing test:**

Carpus r:	-
Carpus l:	-
Fetlock rf:	-
Fetlock lf:	-
Hock r:	-
Hock l:	-
Fetlock rh:	-
Fetlock lh:	+/-
Styfle r:	-
Styfle l:	-

**Radiological examination:**

Navicular rf:	Executed
Navicular lf:	Executed
Fetlock rf:	Executed
Fetlock lf:	Executed
Hock r:	Executed
Hock l:	Executed
Fetlock rh:	Executed
Fetlock lh:	Executed
Styfle r:	Executed
Styfle l:	Executed

**Radiological examination:**

Left front foot: central Synovial invagination, slightly enlarged, navicular bone.

**Conclusion:**

The horse is suitable for sport activity.

  
**Dott. ANDREA TOTO**  
**MEDICO VETERINARIO**  
Isct. Albo n. 919 Ft  
Via Vincenzo Gioberti, 22 - 59100 PRATO (PO)  
Cell. 349 3681259  
P IVA 02449920970 - C.F. TTOND87E13D612S